

# Comparison of Electroanatomical Mapping Systems: Accuracy in Left Atrial Mapping

E. KEVIN HEIST, M.D. PH.D., FRANCESCO PERNA, M.D. PH.D., FADI CHALHOUB, M.D., STEPHAN DANIK, M.D., CONOR BARRETT, M.D., CHRISTOPHER HOUGHTALING, M.S., CLAUDIO TONDO, M.D., PH.D., SRIJOY MAHAPATRA, M.D., JEREMY RUSKIN, M.D., and MOUSSA MANSOUR, M.D.

From the Cardiac Arrhythmia Service, Massachusetts General Hospital and Harvard Medical School, Boston, Massachusetts

**Background:** Current 3D mapping systems have difficulty rendering complex cardiac structures. Different electroanatomical mapping software has been recently developed which uses a mathematical algorithm to improve interpolation between mapped points and delineation of closely spaced structures. This study tested the feasibility and accuracy of this software in comparison to traditional software.

**Methods:** In vivo 3D impedance-based mapping using a multielectrode catheter with a single geometry point cloud was performed in the left atria and pulmonary veins (PV) in 23 patients undergoing catheter ablation for atrial fibrillation. The maps were analyzed with traditional (NavX, St. Jude Medical, Minnetonka, MN, USA), either with or without multichamber mapping versus St. Jude OneModel™ software and dimensions of cardiac chambers in human studies were compared to preprocedural computed tomographic (CT) or magnetic resonance (MR) scans to determine the relative accuracy of the maps.

**Results:** Maps created by the OneModel software provided greater detail of complex cardiac structures compared to traditional software. Comparison of the left atrial/pulmonary vein electroanatomical maps with the CT and MR scans as reference standard demonstrated significantly less error in measurement of all PV ostial long- and short-axis dimensions, inter-PV distance, and ridge width (left PV to left atrial appendage) with the OneModel versus traditional software ( $P < 0.001$  for all dimensions measured).

**Conclusions:** The OneModel software produces maps that are more accurate in rendering complex cardiac structures compared to traditional software. (PACE 2013; 36:626–631)

**ablation, atrial fibrillation, electrophysiology—clinical, mapping**

## Introduction

Electroanatomical mapping (EAM) systems have been widely adopted to facilitate mapping and ablation of complex cardiac arrhythmias such as atrial fibrillation (AF).<sup>1</sup> Image integration (typically integration of either computed tomographic [CT] or magnetic resonance [MR] images with

electroanatomic maps) may also be used to allow mapping and ablation within highly detailed cardiac chambers, but accurate image integration is also dependent on the initial creation of accurate electroanatomic maps.<sup>2–6</sup> Multiple EAM systems have been developed for this purpose: the two in most frequent worldwide clinical use currently for catheter ablation of AF are the CARTO system from Biosense Webster (Diamond Bar, CA, USA), and the EnSite NavX system from St. Jude Medical (Minnetonka, MN, USA).<sup>7,8</sup>

The EnSite Velocity System from St. Jude Medical has been clinically available for several years and allows for rapid creation of EAM from multipolar catheters.<sup>9,10</sup> These maps have traditionally been limited in their ability to delineate fine structures such as PVs, however. For this reason, techniques such as multisurface mapping (the creation of separate maps for structures such as the left atrial [LA] body and the separate PVs and left atrial appendage, with eventual fusion of all mapped structures into a single image) have been employed to create more accurate maps. Recently, the OneModel™ software (St. Jude Medical) has become available to

---

Disclosures: Authors report varying degrees of industry support. EKH: Biosense Webster, Biotronik, Boston Scientific, Sorin, St. Jude Medical. FP, FC, and CB: None. SD: Boston Scientific, St. Jude Medical. CH: St. Jude Medical (employee). CT: Biotronik, Medtronic, St. Jude Medical. SM: St. Jude Medical (employee). JR: Astellas/Cardiome, Biosense Webster, Boston Scientific, CardioFocus, CardioInsight; CryoCath; Medtronic, Med-IQ, Pfizer, Portola; St. Jude Medical, Third Rock Ventures. MM: St. Jude Medical, Biosense Webster, MC 10, Cardiofocus, Rhythmia, Boston Scientific, Voyage Medical.

Address for reprints: Moussa Mansour, M.D., Cardiac Arrhythmia Service and Cardiac Unit, Massachusetts General Hospital, Gray 109, 55 Fruit St, Boston, MA 02114. Fax: 617-724-1241; e-mail: mmansour@partners.org

Received May 23, 2012; revised November 7, 2012; accepted December 9, 2012.

doi: 10.1111/pace.12095

facilitate rapid and accurate mapping of complex cardiac structures in a single map. In this study, we sought to compare the relative accuracy of the traditional EnSite Velocity System compared to the OneModel software during electroanatomical mapping in patients undergoing pulmonary vein (PV) isolation (PVI) for AF. Preprocedural CT and MR scans of the left atrium and PVs were used as the reference standard for comparison with electroanatomical maps.

## Methods

### Mapping Systems

The traditional EnSite Velocity geometry method assumes a center and all points on the geometry must be in a line of sight to the center and no holes are allowed in the geometry. The OneModel software assumes no center and holes are allowed. Thus, in the traditional geometry, any point that is taken will connect in a straight line back to the center. If a branch of a PV is mapped, for example, any point in the branch will connect back to the center of the LA in a straight line. The PV branch therefore may not show up as a separate structure, depending on the orientation of the branch relative to the central point of the map. With OneModel, each point is taken independently. If three points are close enough (default 5 mm) they will connect to each other. If a group of points is not close enough to the main LA geometry, they will be left disconnected. Thus, OneModel allows for PV and LA to be made as a single geometry.

### Mapping Study

Twenty-three patients undergoing catheter-based PVI for AF were studied. Demographic variables are described in Table I. All patients signed written, informed consent for the procedure. All patients received preprocedural CT or MR scans of the LA and PVs as previously described.<sup>3</sup> All procedures were performed under general anesthesia. Right and left femoral venous access was obtained. A decapolar catheter was placed in the coronary sinus. Under fluoroscopic and intracardiac echocardiographic (ICE) (Acu Nav Diagnostic Ultrasound Catheter, Siemens Medical Systems, Issaquah, WA, USA) guidance, two trans-septal punctures were performed via the right femoral vein, and 8 Fr SL1 (Daig St. Jude Medical) and 8.5-Fr Agilis sheaths (St. Jude Medical) were advanced into the left atrium. Intravenous heparin bolus was given before the trans-septal punctures and as a continuous infusion during the procedure with a goal activated clotting time of 300–350 seconds.<sup>10</sup>

**Table I.**

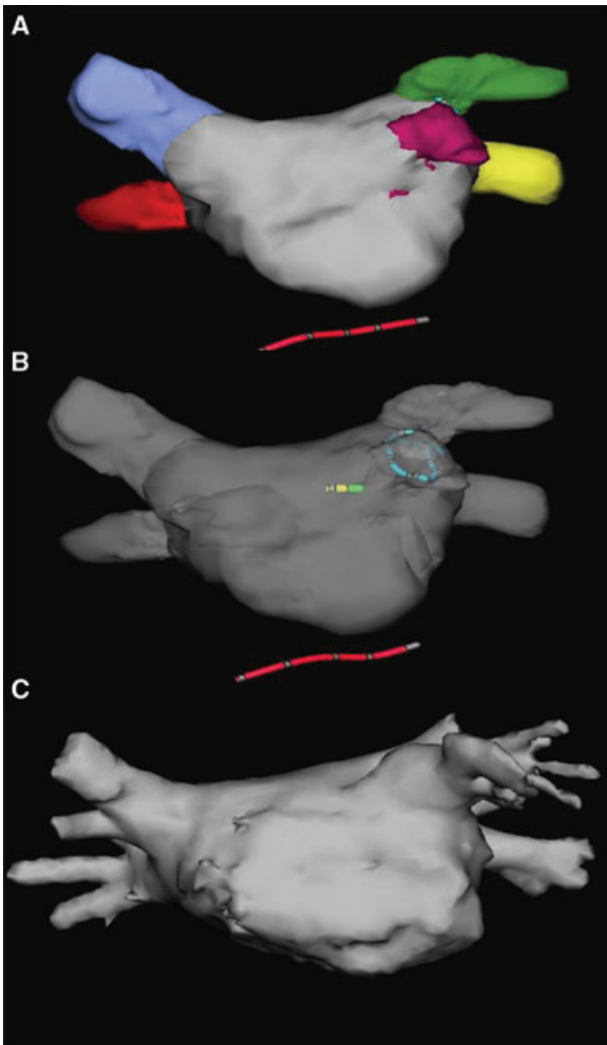
Patient Demographics (n = 23)

Age (years)	59 ± 6
Gender (% female)	30%
Repeat AF ablation	39%
Paroxysmal/persistent AF	70%/30%
Prior stroke	13%
AAD at time of ablation	65%
LA size (mm)	43 ± 6
LVEF (%)	59 ± 10
Coronary artery disease	22%
Beta blocker therapy	65%
ACE-I or ARB therapy	35%

ACE-I = angiotensin-converting enzyme inhibitor; ARB = angiotensin receptor blocker; AF = atrial fibrillation; AAD = antiarrhythmic drug; LA = left atrial; LVEF = left ventricular ejection fraction.

Mapping of the left atrium and PVs was then performed using a multipolar 20-electrode mapping catheter (circular Lasso catheter or multispline Penta-Ray catheter, Biosense Webster, or AFocus DL, St. Jude Medical) to create a point cloud of the LA and PVs using EnSite Velocity software. A single-point cloud was created for each patient, with subsequent off-line analysis using the three different strategies. Each point cloud was then exported into a workstation using EnSite Velocity 3.0.1 software. Three separate electroanatomic maps were then created from each point cloud using (1) the traditional software to create a single map, (2) the traditional software with multisurface modeling (creating separate structures for the LA body, each PV, and the left atrial appendage [LAA], and then fusing these structures together into a single map) (Fig. 1), or (3) using the OneModel software to create a single map. Field scaling was employed for all electroanatomical maps created. The maps created with each method were then compared to preprocedural CT or MR scans of the LA and PVs, with measurements of the short- and long-axis dimensions at the ostia of all four PVs, the distance between the ostia of the left superior PV and the right superior PV, the distance between the antra of the left inferior PV and the right inferior PV, and the width of the ridge separating the left superior PV from the LAA as previously described.<sup>10,11</sup>

Using the traditional multisurface electroanatomic maps and ICE for guidance (the OneModel software was investigational at the time these procedures were performed and therefore was not used to direct ablation), isolation of all pulmonary veins using wide-area antral ablation and verification of entrance block



**Figure 1.** Multisurface modeling using traditional NavX software. (A) Six separate electroanatomic maps have been created, including the left atrial body (gray), the RSPV/RIPV/LSPV/LIPV (blue/red/green/yellow) and the left atrial appendage (purple) in an anteroposterior view. These six maps have been fused to create a single geometry. (B) The fused map is shown created from the six separate maps. (C) The CT image from the same patient.

using the multielectrode mapping catheter was performed in all patients. Additional ablation, including targeting of complex fractionated atrial electrograms and creation of lines of ablation in the left and right atria were performed in some cases at the discretion of the operator.

### Statistics

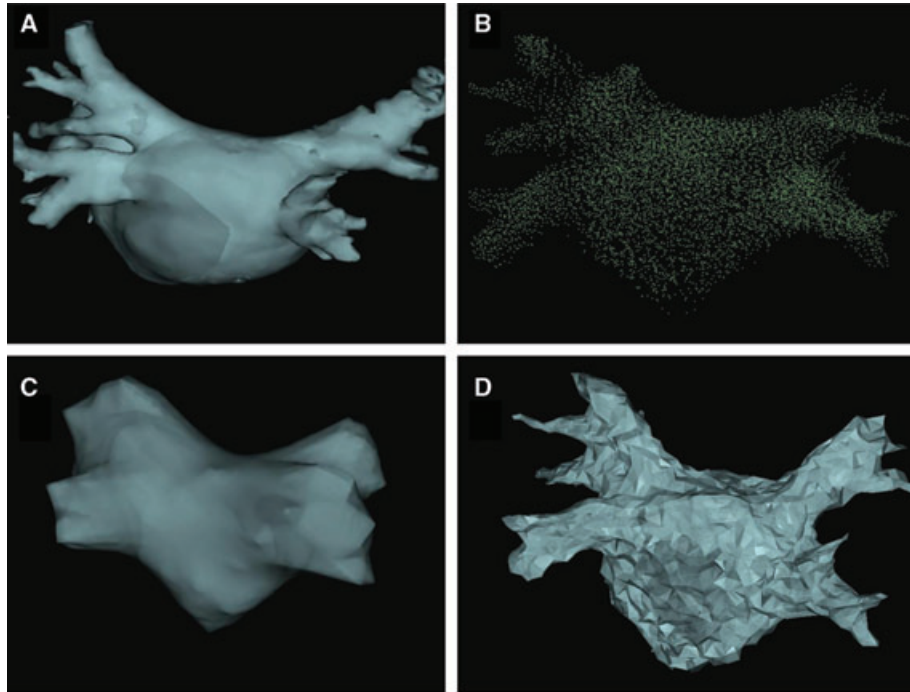
LA and PV measurements are expressed as mean  $\pm$  standard deviation. Pairwise comparisons

were performed to compare the values obtained for PV and LA measurements by CT/MR scanning versus the three different mapping strategies used. Groups were compared utilizing two-tailed unpaired Student's *t*-tests.  $P < 0.05$  was considered statistically significant.

### Results

Electroanatomic mapping was performed within the LA, LAA, and PVs of 23 patients undergoing catheter ablation procedures for AF. The point cloud created from each patient was then utilized to create electroanatomic maps using the traditional software (with and without multisurface modeling) and using the OneModel software (Fig. 2). Compared to preacquired CT/MR images used as a reference standard, the diameters of the PVs when analyzed by the traditional software (particularly when not using multisurface modeling) were substantially larger than the CT/MR images, while these diameters when analyzed by the OneModel software were much closer to the measurements obtained from the CT/MR images (Table II). When directly comparing the difference between the three mapping methodologies using pairwise comparisons of values obtained with each mapping method (traditional  $\pm$  multisurface modeling or OneModel), the OneModel software resulted in significantly smaller pairwise differences from the CT/MR image compared to the traditional software (with or without multisurface modeling). This was true for all measurements (short and long axis of each PV, distance from left superior pulmonary vein-right superior pulmonary vein [LSPV-RSPV] and left inferior pulmonary vein-right inferior pulmonary vein [LIPV-RIPV]), and width of the ridge between the LAA and the left pulmonary veins ( $P < 0.001$  for all dimensions measured) (Table III). The largest absolute differences recorded for single measurements described above compared to the CT/MR image were as follows: OneModel: 5 mm, traditional: 35 mm, traditional multisurface: 12 mm.

To determine whether left atrial size impacted accuracy of measurement using the OneModel software, a median left atrial size cut-off was selected, and the 11/23 patients with the larger left atria were compared to the 12/23 patients with the smaller left atria. Pairwise comparisons were made of the same anatomical measurements shown in Table III, comparing values obtained with OneModel versus CT/MR. There was a small but statistically significant larger overall absolute difference in measurement between OneModel versus CT/MR for the patients with larger versus smaller LA ( $1.14 \pm 0.79$  mm vs  $0.95 \pm 0.75$  mm, respectively,  $P = 0.047$ ).



**Figure 2.** Mapping of the human left atrium and pulmonary veins using the traditional versus the OneModel software. (A) A posteroanterior view of a CT image of the posterior left atrium and pulmonary veins from a patient prior to catheter ablation of AF. (B) The point cloud created by mapping this chamber with a multipolar catheter. Points are shown in green. (C) Generation of an electroanatomic map from this point cloud using the traditional software. (D) Generation of an electroanatomic map from this same point cloud using the OneModel software, producing greater anatomic detail, particularly in regard to pulmonary vein branches.

**Table II.**

Pulmonary Vein Ostial and Left Atrial Measurements

	OM	Trad	Trad-MS	CT/MR
LSPV-l	24.5 ± 7.0	36 ± 10.7	25.2 ± 8.4	24.3 ± 7.1
LVPV-s	15.5 ± 4.3	29.2 ± 8.4	18.2 ± 3.8	16.2 ± 3.8
LIPV-l	14.0 ± 8.0	21.7 ± 12.8	15.5 ± 9.0	13.8 ± 7.9
LIPV-s	10.1 ± 6.5	20.0 ± 12.7	11.0 ± 6.3	10.1 ± 6.6
RSPV-l	22.2 ± 4.4	35.8 ± 9.7	26.3 ± 5.1	21.9 ± 4.4
RSPV-s	19.9 ± 4.8	29.4 ± 7.8	19.4 ± 6.1	20.4 ± 5.0
RIPV-l	19.2 ± 4.8	26.5 ± 7.9	18.5 ± 5.8	19.4 ± 6.2
RIPV-s	19.0 ± 6.0	25.2 ± 8.6	17.2 ± 5.2	18.9 ± 5.7
LAA ridge	4.0 ± 1.9	2.9 ± 5.1	5.3 ± 2.7	4.2 ± 1.7
LS-RS	23.0 ± 8.3	26.9 ± 8.8	22.0 ± 7.6	23.2 ± 7.8
LI-RI	34.8 ± 7.5	36.1 ± 8.1	36.4 ± 12.0	35.1 ± 7.6

All measurements are in mm ± standard deviation OM = OneModel™; Trad = traditional mapping; Trad-MS = traditional mapping with multisurface reconstruction; CT/MR = computed tomographic or magnetic resonance image of the left atrium and pulmonary veins; LSPV = left superior pulmonary vein; LIPV = left inferior pulmonary vein; RSPV = right superior pulmonary vein; RIPV = right inferior pulmonary vein. -l = long axis; -s = short axis; LAA ridge = width of the ridge separating the left pulmonary veins from the left atrial appendage. LS-RS = distance from the ostia of the LSPV to the RSPV. LI-RV = distance from the ostia of the LIPV to the RIPV.



**Table III.**

Pairwise Comparison of Pulmonary Vein Ostial and Left Atrial Measurements When Comparing Three Mapping Methods versus CT/MR

	OM vs CT/MR	Trad vs CT/MR	Trad-MS vs CT/MR
LSPV-I	0.8 ± 0.6	11.9 ± 6.6	3.1 ± 1.1
LVPV-s	1.3 ± 0.8	13.0 ± 6.3	3.3 ± 1.3
LIPV-I	0.6 ± 0.6	7.8 ± 6.2	2.6 ± 1.7
LIPV-s	0.9 ± 0.8	10.0 ± 7.8	3.0 ± 1.8
RSPV-I	1.0 ± 0.6	13.9 ± 8.0	4.5 ± 1.5
RSPV-s	1.1 ± 0.6	9.2 ± 7.9	3.5 ± 1.4
RIPV-I	0.9 ± 0.8	8.1 ± 4.5	3.7 ± 1.7
RIPV-s	1.1 ± 0.7	7.4 ± 6.5	2.7 ± 1.1
LAA ridge	1.0 ± 0.7	4.3 ± 2.3	3.2 ± 0.8
LS-RS	1.2 ± 0.73	6.9 ± 5.8	3.8 ± 1.3
LI-RI	1.6 ± 1.2	7.5 ± 7.0	7.5 ± 2.3
Overall	1.1 ± 0.8	9.1 ± 6.9	3.7 ± 2.0

*Note:* P < 0.001 when comparing OneModel versus either traditional or traditional multisurface for all measurements of all dimensions listed above.

Abbreviations are as per Table II.

These values represent the means of pairwise comparisons (mm ± standard deviation) between measurements obtained with the three mapping methods (OneModel, traditional, and traditional multisurface) compared to the CT/MR scan used as the standard.

### Discussion

Catheter ablation of arrhythmias such as AF requires manipulation of the ablation catheter within complex anatomical structures such as the LA and PVs.<sup>11,12</sup> EAM systems provide operators with information regarding catheter position relative to these complex structures.<sup>10</sup> Accuracy of these maps is important, both for procedural safety and efficacy. Poor maps could lead to poor tissue contact with inadequate ablation lesion formation, excessive catheter force with the possibility for cardiac perforation,<sup>13</sup> or with ablation at inadvertent sites, such as ablation deep within the PVs, leading to the potential for PV stenosis.<sup>12</sup>

In this study, we compared the accuracy of EAMs created using traditional NavX mapping software compared to the OneModel software.

### References

1. Sporton SC, Earley MJ, Nathan AW, Schilling RJ. Electroanatomic versus fluoroscopic mapping for catheter ablation procedures: A prospective randomized study. *J Cardiovasc Electrophysiol* 2004; 15:310–315.
2. Bertaglia E, Bella PD, Tondo C, Proclemer A, Bottoni N, De Ponti R, Landolina M, et al. Image integration increases efficacy of paroxysmal atrial fibrillation catheter ablation: Results from the cartomerge italian registry. *Europace* 2009; 11:1004–1010.
3. Heist EK, Chevalier J, Holmvang G, Singh JP, Ellinor PT, Milan DJ, D'Avila A, et al. Factors affecting error in integration of

Both subjectively and objectively, the OneModel software produced maps which more accurately reflect the cardiac anatomy and dimensions of the reference CT/MR images. The average differences in dimensions of the cardiac structures (compared to CT/MR images) were approximately 1–2 mm (max. 5 mm) with the OneModel software, versus 4–14 mm (max. 35 mm) with the traditional software and 3–7 mm (max. 12 mm) with the traditional software using multisurface modeling.

It is not known what difference in measurement (compared to the CT/MR image) is “acceptable,” and what the impact of these differences will be in regard to clinical safety and efficacy. These differences are substantial and highly statistically significant, however. This is especially relevant in regard to modeling of detailed structures such as the ridge between the left atrial appendage and the PVs, and the branching of the PVs. The traditional software produces improved accuracy when utilizing multisurface modeling (creating separate maps for structures such as the LA body, the LAA, and each separate PV and then fusing these all together). Multisurface modeling is time-consuming and technically challenging, however, and is still less accurate (compared to the CT/MR images) than the OneModel software, which does not require multisurface modeling.

### Limitations

This was a nonrandomized study; therefore, it is not clear whether the relative accuracy of the OneModel software compared to the traditional software will translate into measurable differences in safety and efficacy of the AF ablation procedure. The OneModel software was investigational at the time this study was performed; therefore, maps created using the OneModel software were not directly utilized during ablation procedures in this study.

### Conclusion

The OneModel software produces electroanatomic maps that more closely match reference CT/MR images compared to the traditional mapping software. Further studies will be necessary to determine the impact of these differences in mapping accuracy on procedural time, efficacy, and safety.

4. Hunter RJ, Ginks M, Ang R, Diab I, Goromonzi FC, Page S, Baker V, et al. Impact of variant pulmonary vein anatomy and image integration on long-term outcome after catheter ablation for atrial fibrillation. *Europace* 2010; 12:1691–1697.
5. Kistler PM, Rajappan K, Harris S, Earley MJ, Richmond L, Sporton SC, Schilling RJ. The impact of image integration on catheter ablation of atrial fibrillation using electroanatomic mapping:

## COMPARATIVE ELECTROANATOMICAL MAPPING

- A prospective randomized study. *Eur Heart J* 2008; 29:3029–3036.
6. Powell BD, Packer DL. Does image integration improve atrial fibrillation ablation outcomes, or are other aspects of the ablation the key to success? *Europace* 2009; 11:973–974.
  7. Finlay MC, Hunter RJ, Baker V, Richmond L, Goromonzi F, Thomas G, Rajappan K, et al. A randomised comparison of cartomerge vs. Navx fusion in the catheter ablation of atrial fibrillation: The cavern trial. *J Interv Card Electrophysiol* 2012; 33:161–169.
  8. Khaykin Y, Oosthuizen R, Zarnett L, Wulffhart ZA, Whaley B, Hill C, Giewercer D, et al. Carto-guided vs. Navx-guided pulmonary vein antrum isolation and pulmonary vein antrum isolation performed without 3-D mapping: Effect of the 3-D mapping system on procedure duration and fluoroscopy time. *J Interv Card Electrophysiol* 2011; 30:233–240.
  9. Eitel C, Hindricks G, Dages N, Sommer P, Piorkowski C. Ensite velocity cardiac mapping system: A new platform for 3D mapping of cardiac arrhythmias. *Expert Rev Med Devices* 2010; 7:185–192.
  10. Koruth JS, Heist EK, Danik S, Barrett CD, Kabra R, Blendea D, Ruskin J, et al. Accuracy of left atrial anatomical maps acquired with a multielectrode catheter during catheter ablation for atrial fibrillation. *J Interv Card Electrophysiol* 2011; 32:45–51.
  11. Mansour M, Refaat M, Heist EK, Mela T, Cury R, Holmvang G, Ruskin JN. Three-dimensional anatomy of the left atrium by magnetic resonance angiography: Implications for catheter ablation for atrial fibrillation. *J Cardiovasc Electrophysiol* 2006; 17:719–723.
  12. Calkins H, Kuck KH, Cappato R, Brugada J, Camm AJ, Chen SA, Crijns HJ, et al. 2012 HRS/EHRA/ECAS expert consensus statement on catheter and surgical ablation of atrial fibrillation: Recommendations for patient selection, procedural techniques, patient management and follow-up, definitions, endpoints, and research trial design: A report of the Heart Rhythm Society (HRS) Task Force on Catheter and Surgical Ablation of Atrial Fibrillation. Developed in partnership with the European Heart Rhythm Association (EHRA), a registered branch of the European Society of Cardiology (ESC) and the European Cardiac Arrhythmia Society (ECAS); and in collaboration with the American College of Cardiology (ACC), American Heart Association (AHA), the Asia Pacific Heart Rhythm Society (APHRS), and the Society of Thoracic Surgeons (STS). Endorsed by the governing bodies of the American College of Cardiology Foundation, the American Heart Association, the European Cardiac Arrhythmia Society, the European Heart Rhythm Association, the Society of Thoracic Surgeons, the Asia Pacific Heart Rhythm Society, and the Heart Rhythm Society. *Heart Rhythm* 2012.
  13. Perna F, Heist EK, Danik SB, Barrett CD, Ruskin JN, Mansour M. Assessment of catheter tip contact force resulting in cardiac perforation in swine atria using force sensing technology. *Circ Arrhythm Electrophysiol* 2011; 4:218–224.